Kepler Universitätsklinikum

JKU JOHANNES KEPLER UNIVERSITÄT LINZ

Kinderherz Zentrum Linz
Kepler Universitäts Klinikum

Surgical therapy of infective endocarditis following interventional or surgical pulmonary valve replacement in congenital heart disease patients

Gierlinger G.[1], Sames-Dolzer E.[1], Kreuzer M.[1], Mair Ro.[1], Zierer A.[2], Mair R.[1]

1) *Division of Pediatric and Congenital Heart Surgery, Kepler University Hospital, JKU, Linz, Austria*
2) *Department for Thoracic and Cardiovascular Surgery, Kepler University Hospital, JKU, Linz, Austria*

Objectives

Percutaneous pulmonary valve prostheses (PPVP) and right ventricle to pulmonary artery conduits (RVPAC) are at risk for infective endocarditis (IE) (1,2). In children and adults with congenital heart disease an implantation of a pulmonary valve is frequently necessary. Prosthetic pulmonary valve endocarditis is a conservatively barely manageable, serious life-threatening condition (3-5). The results of surgical pulmonary valve replacements in infective endocarditis were investigated.

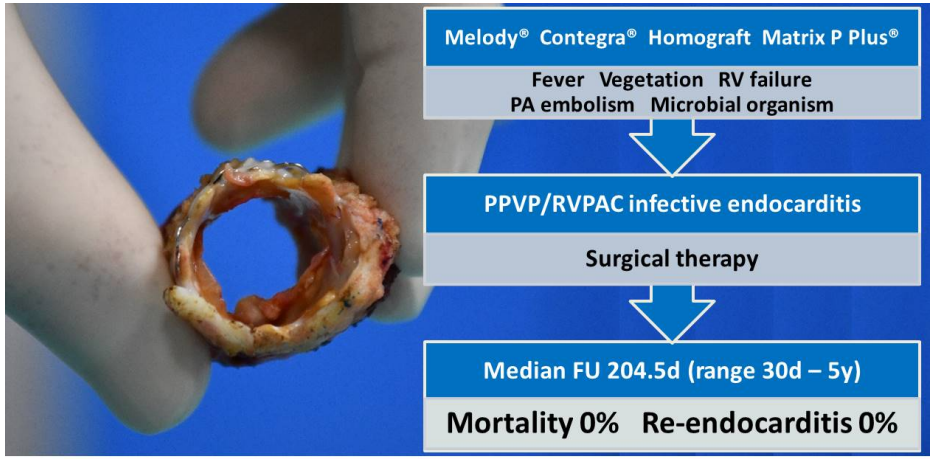

Patients and Methods

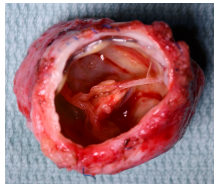

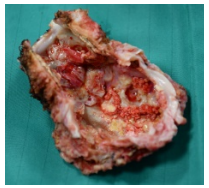

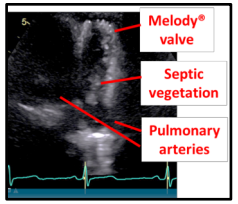

- **n = 20**
- Mean age **15.9 years** [95% CI, 12.3-19.4]
- Mean time: conduit implantation to surgery for IE = 4.9 years
- **Surgical therapy + antibiotic treatment in all patients**
- Removal of infected prosthetic material until pulmonary bifurcation
- Pulmonary homografts as orthotopic RVPAC

Initial diagnosis		Infected conduits	
TOF/DORV	n = 9 (45%)	Melody®	n =11 (55%)
Aortic valve disease	n = 5 (25%)	Contegra®	n = 5 (25%)
TAC	n = 4 (20%)	Homograft	n = 3 (15%)
PA/IVS	n = 1 (5%)	Matrix P Plus®	n = 1 (5%)
Borderline LV	n = 1 (5%)		

Microbial organisms (14 pts. = 70%)	
Streptococcal species	n = 5
Staphylococcus aureus	n = 2
Stapylococcus epidermidis	n = 1
Gram positive cocci	n = 3
HACEK organisms	n = 2
Aspergillus species	n = 1

Results

- **All patients survived**; discharged home infection-free
- Median bypass time **156.5 minutes** [95% CI, 111.9-223.7]
- Aortic cross clamp time (12 pts.) mean **64.1 minutes**
- Post-operative complications: **one patient** (bleeding)
- **No ECMO therapy** and **no neurological complications**
- Median ICU stay: **3.0 days** [95% CI, 2.0-4.7]
  Median hospital time: **25.0 days** [95% CI, 19.2-42.0]
- FU: **30d – 5y**; in total 30.1 pt. years (median 204.5d)

No mortality No re-endocarditis

Conclusion

- Surgical therapy after PPVP and RVPAC is **safe and effective**
- **All our patients were free of infection at time of discharge**

Early surgical referral of IE should be pursued to avoid

- right ventricular failure
- septic emboli
- intracardiac expansion
- antibiotic resistance

Referenzen:

1. Mery CM, Guzmán-Pruneda FA, De León LE, et al. Risk factors for development of endocarditis and reintervention in patients undergoing right ventricle to pulmonary artery valved conduit placement. J Thorac Cardiovasc Surg. 2016;151(2):432-441.e4412.
2. Amat-Santos IJ, Ribeiro HB, Urena M, et al. Prosthetic valve endocarditis after transcatheter valve replacement: a systematic review. JACC Cardiovasc Interv. 2015;8(2):334-346.
3. Rebollal-Leal F, Felipe-Abella R, Gutierrez-García F, A Mestres C, Bautista-Hernandez V. Prosthetic pulmonary valve and conduit endocarditis in congenital heart disease. Asian Cardiovasc Thorac Ann. 2019;27(4):265-270.
4. Miranda WR, Connolly HM, Bonnichsen CR, et al. Prosthetic pulmonary valve and pulmonary conduit endocarditis: clinical, microbiological and echocardiographic features in adults. Eur Heart J Cardiovasc Imaging. 2016;17(8):936-943. Blindtext in 18 pt
5. Malekzadeh-Milani S, Ladouceur M, Iserin L, Bonnet D, Boudjemline Y. Incidence and outcomes of right-sided endocarditis in patients with congenital heart disease after surgical or transcatheter pulmonary valve implantation. J Thorac Cardiovasc Surg. 2014;148(5):2253-2259.